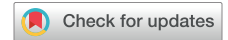

Vasa previa: time to make a difference



Yinka Oyelese, MD

There is perhaps no more catastrophic event for the fetus than rupture of a vasa previa.¹ Vasa previa, defined as unprotected fetal vessels running through the membranes over the cervix, often ruptures when the membranes rupture, frequently leading to sudden fetal death.¹⁻⁴ This used to be a feared condition among obstetricians, first because of its devastating consequences, but also because, until recently, it was rarely diagnosed prior to the rupture and hence was considered unpreventable.¹

We have previously shown that when vasa previa is not diagnosed prenatally, approximately 56% of babies die, while survival approaches 100% when the diagnosis is made prenatally.⁴ Fortunately, over the past 30 years or so, ultrasound has made it possible to diagnose the condition prenatally, which allows planned cesarean delivery in the late preterm period prior to spontaneous rupture of membranes, avoiding the high risk for perinatal death.¹⁻¹³ There are now several studies that have documented universally excellent outcomes when vasa previa is diagnosed prenatally, and planned cesarean delivery is undertaken before the membranes rupture.¹⁻¹²

Unfortunately, there has been some reluctance to adopt a protocol of routinely screening for vasa previa, primarily for 3 major reasons: (1) doubts about the accuracy of ultrasound in diagnosing vasa previa when applied in the general population,¹⁴ (2) concerns about false-positive rates,¹⁴ and (3) medicolegal and liability concerns.¹³

Two fairly large studies published in this edition of the journal^{15,16} add to the already extensive body of evidence that the overwhelming proportion of cases of vasa previa can be diagnosed prenatally and that this diagnosis and planned cesarean delivery before labor lead to almost universally excellent outcomes.

These studies also find, not unsurprisingly, given what we know from our experience with placenta previa, that a proportion of cases diagnosed in early pregnancy will resolve prior to delivery.^{15,16} The investigators of both these studies

are to be commended. Their findings mean that women with vasa previa diagnosed early in pregnancy may not necessarily need hospitalization and early delivery. Thus, women in whom vasa previa is diagnosed early in pregnancy should be counseled of the possibility of resolution and should be evaluated later in pregnancy, at about 32 weeks.^{15,16}

This brings an important question: what is meant by resolution? Klahr et al¹⁵ define vasa previa as vessels that lie within a 2 cm radius of the internal os and thus define resolution as vessels greater than that distance from the internal os, while Erfani et al¹⁶ do not give a definition of resolution. Sinkey et al³ and Rebarber et al⁶ have previously used this definition of vasa previa as unprotected fetal vessels within 2 cm of the internal cervical os. However, it is not clear whether the rationale of using a distance of 2 cm was based on evidence.

It is likely extrapolated from data regarding placenta previa, in which it has been found that women with a low-lying placenta with a lower placental edge 2 cm or greater from the internal os may safely deliver vaginally.^{17,18} However, if a placenta previa bleeds, it has little impact on safe delivery. Conversely, if vessels in a vasa previa rupture, it would likely lead to fetal death.

In theory at least, any unprotected fetal vessels that lie within a 5 cm radius of the internal os are at risk for rupture, either during labor (given that the cervix dilates to 10 cm) or when the membranes rupture. When an accoucheur uses an amniocentesis needle, intrauterine pressure catheter, or other such device in labor, unprotected vessels that are close to the internal os of the cervix may be ruptured. For this reason, it would be prudent to be more conservative in defining a safe distance for vessels to be from the internal os to allow labor.

In fact, Klahr et al¹⁵ found a case of intrauterine death at 33 weeks following vaginal bleeding in twin A in which the vasa previa was said to have resolved at 2.8 cm from the internal os based on examination just 2 weeks earlier, at 31 weeks. Thus, it can be argued that this vasa previa did not resolve. Unfortunately, the distance from the internal os at which fetal vessels can be considered safe will be difficult to study. In my view, however, ethical principles of autonomy do dictate that the patient should be counseled of unprotected vessels in the lower uterine segment, irrespective of distance from the internal os, of potential risks of rupture and be allowed to participate in the decision making regarding mode of delivery.

Nonetheless, these 2 current studies do present very useful information: a significant proportion of cases of vasa previa will resolve by delivery. Klahr et al¹⁵ found resolution in 39% of cases, while Erfani et al¹⁶ found resolution in 19 of 136 of cases (14%). Both studies did find, as with prior studies on placenta previa, that the later in gestation the diagnosis is made, the less the chance of resolution.¹⁹

From the Atlantic Health System, Morristown, NJ.

Received July 15, 2019; revised Aug. 9, 2019; accepted Aug. 21, 2019.

Dr Oyelese is an author for UpToDate and the BMJ for which he has received royalties. He was also on the Speake's Bureau for Hologic in 2017 and has spoken on fetal fibronectin, receiving honoraria and travel expenses.

The author reports no conflict of interest.

Corresponding author: Yinka Oyelese, MD. yinkamd@aol.com

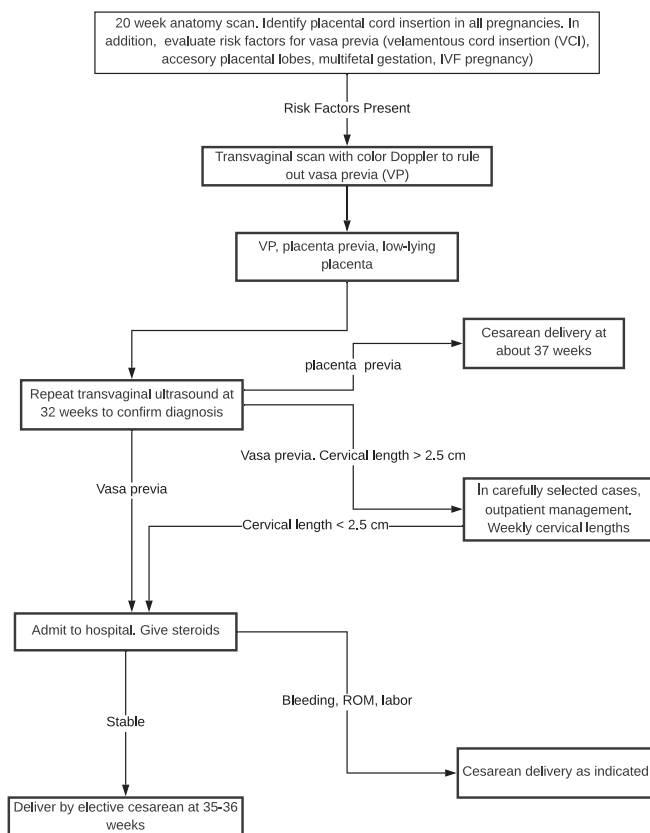
0002-9378/free

© 2019 Published by Elsevier Inc.

<https://doi.org/10.1016/j.ajog.2019.08.034>

➤ Related articles, pages 644 and 646

FIGURE
Algorithm for screening for vasa previa and subsequent management



Oyese. Vasa previa: time to make a difference. *Am J Obstet Gynecol* 2019.

It is important to emphasize that to decide that a vasa previa has resolved, it is crucial that the sonographer be able to adequately image the region over the cervix. This often can be difficult in the third trimester, when the presenting part is frequently closely applied to the cervix. A recent report does document a case of vasa previa in which the vessels could not be seen because the head was well applied to the cervix.²⁰ This patient was thought to not have a vasa previa. However, on displacement of the fetal head, the vessels became obvious. This case would have been missed if the fetal head could not be displaced in a cephalad direction.²⁰

In conclusion, these 2 studies by Khlar et al¹⁵ and Erfani et al¹⁶ add to the body of evidence confirming that vasa previa can be almost universally diagnosed in the antepartum period and have excellent outcomes with timely cesarean delivery. Perinatal death from vasa previa is for the most part a preventable event. There is perhaps no other condition in which prenatal diagnosis makes such a profound difference between survival and death for the fetus and/or neonate.¹³

Ultrasound is now universally used, and while it will detect countless conditions, very few, if any, of these conditions allow for a clear simple intervention to save fetal lives, as does

the prenatal diagnosis of vasa previa.¹³ Given that ultrasound is so accurate in the prenatal diagnosis of vasa previa¹² and that there is an effective intervention to prevent perinatal death, it is time that there is a more universal approach of screening and diagnosis of this condition.¹³

There are those who argue that a randomized controlled trial must be conducted before instituting such a policy. Unfortunately, given the relative rarity of this condition, a randomized trial will not be possible, and even if it were, in my opinion, it would be ethically unacceptable to allow babies to die a preventable death when there is clearly evidence of the accuracy of diagnosis and the effectiveness of the intervention in preventing perinatal death.

Risk factors for vasa previa include a second-trimester low-lying placenta/placenta previa (regardless of resolution), pregnancies with bilobed or succenturiate-lobed placentas, pregnancies resulting from in vitro fertilization, and multifetal pregnancies.^{1,2} Some have recommended targeted screening in pregnancies in which these risk factors are present. However, Klahr et al¹⁵ found an absence of risk factors in 6% of cases of vasa previa.

In our previous study, we found that 14.3% of cases of vasa previa had no known risk factors.⁸ A risk-based screening algorithm would likely have missed those cases. The American Institute of Ultrasound in Medicine recommends that the placental cord insertion be identified whenever technically feasible.²¹ In my view, an attempt should always be made to identify the placental cord insertion because it has been shown that it is achievable in between 99% and 100% of second-trimester sonograms and takes very little time, making no extra demand on equipment and personnel.^{22,23}

In addition, in cases with the aforementioned risk factors, the region over the cervix should also be examined with Doppler.^{8,9} Pregnancies with second-trimester low-lying placentas should have a transvaginal ultrasound with Doppler at about 32 weeks to confirm placental migration and to rule out vasa previa.^{2,24} An algorithm for screening for vasa previa, and management of the condition is shown in the Figure.²⁵

The transvaginal sonographic measurement of the cervical length is now widely performed to predict risk for preterm delivery. Adding color Doppler to these examinations will help detect even more cases of vasa previa, further decreasing the perinatal mortality from this condition.

Finally, while those with vasa previa are frequently delivered at 34–35 weeks, the recommendations for such early delivery were made before the risks associated with late preterm delivery had been fully recognized. Our experience has been that stable cases can be safely delivered at 36 weeks without worsening outcomes. Thus, I recommend that stable cases be delivered at 36 weeks.

Klahr et al¹⁵ found a vasa previa prevalence of 2.95 per 1000 pregnancies (1 of 338) in their cohort.¹⁶ Hasegawa et al²⁶ previously found a prevalence of 1 in 365 pregnancies. Thus, vasa previa is likely more common than previously thought. A unique opportunity exists to prevent perinatal

mortality from this condition. Prenatal diagnosis accompanied by timely cesarean delivery will prevent deaths from vasa previa. ■

REFERENCES

- Oyelese KO, Turner M, Lees C, Campbell S. Vasa previa: an avoidable obstetric tragedy. *Obstet Gynecol Surv* 1999;54:138–45.
- Oyelese Y, Smulian JC. Placenta previa, placenta accreta, and vasa previa. *Obstet Gynecol* 2006;107:927–41.
- Sinke RG, Odibo AO, Dashe JS. Society of Maternal-Fetal (SMFM) Publications Committee. #37: diagnosis and management of vasa previa. *Am J Obstet Gynecol* 2015;213:615–9.
- Oyelese Y, Catanzarite V, Prefumo F, et al. Vasa previa: the impact of prenatal diagnosis on outcomes. *Obstet Gynecol* 2004;103(5 Pt 1):937–42.
- Oyelese KO, Schwärzler P, Coates S, Sanusi FA, Hamid R, Campbell S. A strategy for reducing the mortality rate from vasa previa using transvaginal sonography with color Doppler. *Ultrasound Obstet Gynecol* 1998;12:434–8.
- Rebarber A, Dolin C, Fox NS, Klauser CK, Saltzman DH, Roman AS. Natural history of vasa previa across gestation using a screening protocol. *J Ultrasound Med* 2014;33:141–7.
- Bronsteen R, Whitten A, Balasubramanian M, et al. Vasa previa: clinical presentations, outcomes, and implications for management. *Obstet Gynecol* 2013;122(2 Pt 1):352–7.
- Kulkarni A, Powel J, Aziz M, et al. Vasa previa: prenatal diagnosis and outcomes: thirty-five cases from a single maternal-fetal medicine practice. *J Ultrasound Med* 2018;37:1017–24.
- Catanzarite V, Cousins L, Daneshmand S, et al. Prenatally diagnosed vasa previa: a single-institution series of 96 cases. *Obstet Gynecol* 2016;128:1153–61.
- Swank ML, Garite TJ, Maurel K, et al. Obstetrix Collaborative Research Network. Vasa previa: diagnosis and management. *Am J Obstet Gynecol* 2016;215:223.e1–6.
- Sullivan EA, Javid N, Duncombe G, et al. Vasa previa diagnosis, clinical practice, and outcomes in Australia. *Obstet Gynecol* 2017;130:591–8.
- Ruiter L, Kok N, Limpens J, et al. Systematic review of accuracy of ultrasound in the diagnosis of vasa previa. *Ultrasound Obstet Gynecol* 2015;45:516–22.
- Atkinson A, Oyelese Y. Vasa previa: the case for routine screening. *Fetal Matern Med Rev* 2014;24:277–88.
- Jauniaux E, Alfirevic Z, Bhide AG, Burton GJ, Collins SL, Silver R. Royal College of Obstetricians and Gynaecologists. Vasa praevia: diagnosis and management: Green-top Guideline No. 27b. *BJOG* 2019;126:e49–61.
- Klahr R, Fox NS, Zafman K, Hill MB, Connolly CT, Rebarber A. Frequency of spontaneous resolution of vasa previa with advancing gestational age. *Am J Obstet Gynecol* 2019;221:646.e1–7.
- Erfani H, Haeri S, Shainker SA, et al. Vasa Previa: a multicenter retrospective cohort study. *Am J Obstet Gynecol* 2019;221:644.e1–5.
- Oppenheimer LW, Farine D, Ritchie JW, Lewinsky RM, Telford J, Fairbanks LA. What is a low-lying placenta? *Am J Obstet Gynecol* 1991;165(4 Pt 1):1036–8.
- Bhide A, Prefumo F, Moore J, Hollis B, Thilaganathan B. Placental edge to internal os distance in the late third trimester and mode of delivery in placenta praevia. *BJOG* 2003;110:860–4.
- Dashe JS, McIntire DD, Ramus RM, Santos-Ramos R, Twickler DM. Persistence of placenta previa according to gestational age at ultrasound detection. *Obstet Gynecol* 2002;99(5 Pt 1):692–7.
- Kagan KO, Hoopmann M, Sonek J. Vasa previa: easy to miss. *Ultrasound Obstet Gynecol* 2018;51:283–4.
- American Institute of Ultrasound in Medicine. AIUM practice guideline for the performance of obstetric ultrasound examinations. *J Ultrasound Med* 2013;32:1083–101.
- Nomiyama M, Toyota Y, Kawano H. Antenatal diagnosis of velamentous umbilical cord insertion and vasa previa with color Doppler imaging. *Ultrasound Obstet Gynecol* 1998;12:426–9.
- Allaf MB, Andrikopoulou M, Crnosija N, Muscat J, Chavez MR, Vintzileos AM. Second trimester marginal cord insertion is associated with adverse perinatal outcomes. *J Matern Fetal Neonatal Med* 2019;32:2979–84.
- Reddy UM, Abuhamad AZ, Levine D, Saade GR. Fetal Imaging Workshop Invited Participants. Fetal imaging: executive summary of a joint *Eunice Kennedy Shriver* National Institute of Child Health and Human Development, Society for Maternal-Fetal Medicine, American Institute of Ultrasound in Medicine, American College of Obstetricians and Gynecologists, American College of Radiology, Society for Pediatric Radiology, and Society of Radiologists in Ultrasound fetal imaging workshop. *Am J Obstet Gynecol* 2014;210:387–97.
- Vintzileos AM, Ananth CV, Smulian JC. Using ultrasound in the clinical management of placental implantation abnormalities. *Am J Obstet Gynecol* 2015;213:S70–7.
- Hasegawa J, Nakamura M, Ichizuka K, Matsuoka R, Sekizawa A, Okai T. Vasa previa is not infrequent. *J Matern Fetal Neonatal Med* 2012;25:2795–6.